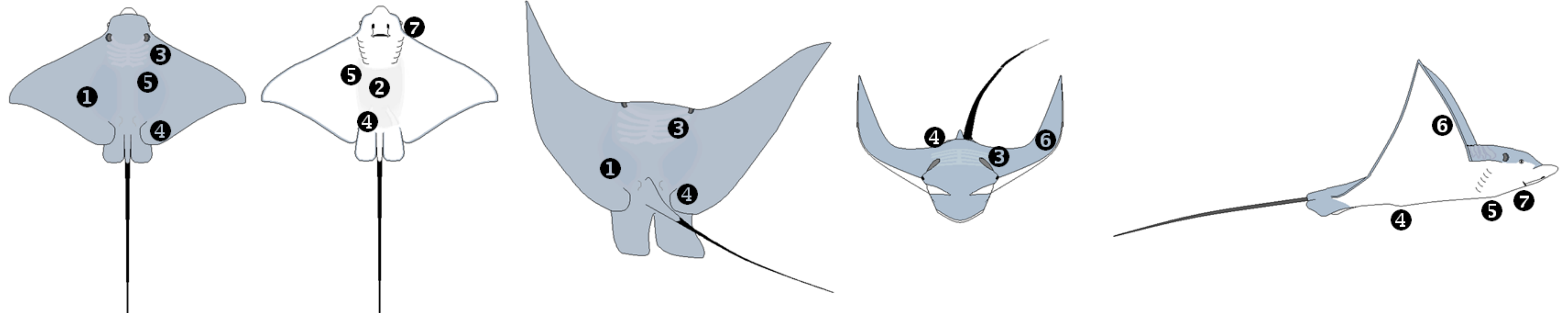
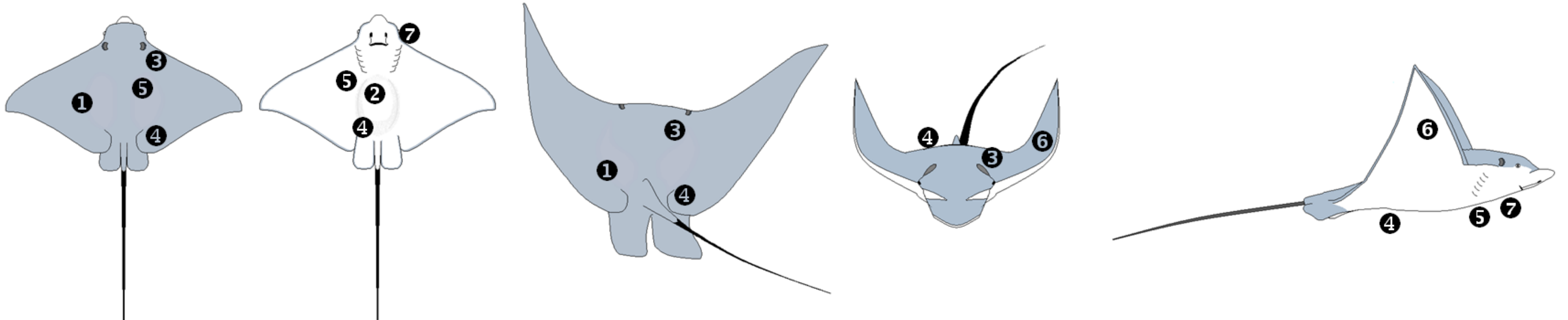


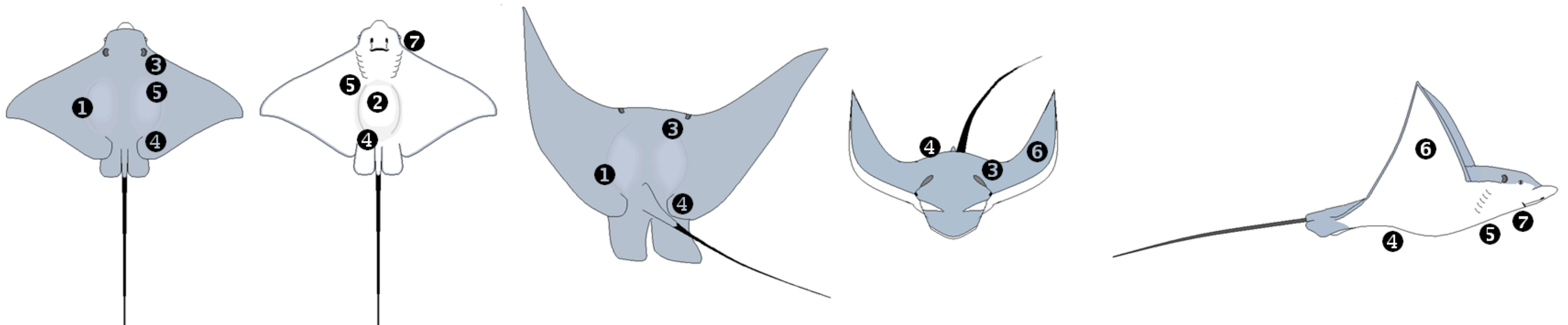
a. **Body Condition Score 1:** (1) Dorsal coelomic surface: pectoral musculature shows concavity nearest midline; (2) Ventral coelomic surface: moderate to severe concavity (sunken appearance); (3) Gill arches: visible; (4) Pelvic girdle: visible dorsally and ventrally; (5) Pectoral girdle: visible dorsally and ventrally; (6) Wing: no thickening; (7) Head: skin around eye and mouth show concavity; skin around mouth may appear stretched.



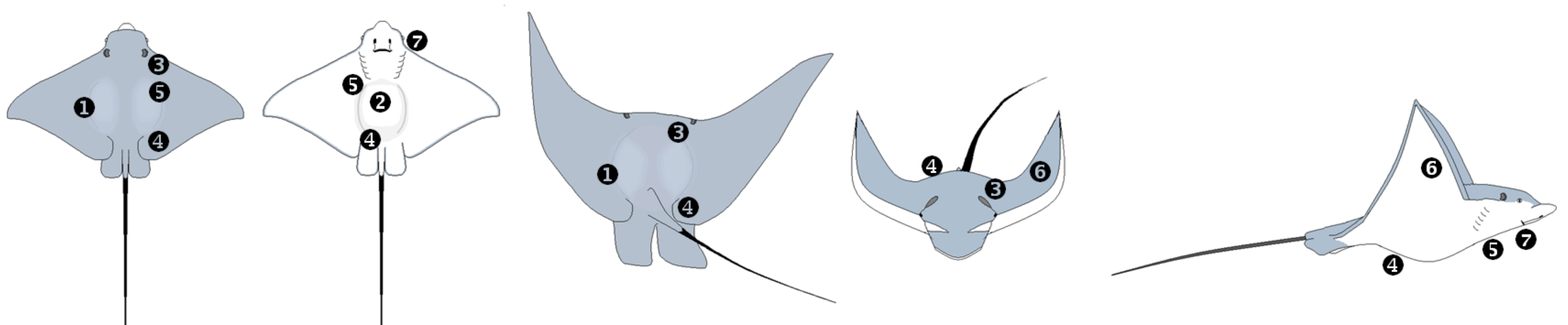
b. **Body Condition Score 2:** (1) Dorsal coelomic surface: pectoral musculature shows slight concavity or flush nearest midline; (2) Ventral coelomic surface: mild concavity or flush with body wall; (3) Gill arches: mildly visible; (4) Pelvic girdle: mildly visible dorsally and ventrally; (5) Pectoral girdle: mildly visible dorsally and ventrally; (6) Wing: thickening mild nearest the midline; (7) Head: normal (no concavity noted in skin near eyes or mouth).



c. **Body Condition Score 3:** (1) Dorsal coelomic surface: pectoral musculature shows mild convexity (distension) nearest the midline; (2) Ventral coelomic surface: no concavity; mild convexity starting past the last gill slit; (3) Gill arches: not visible; (4) Pelvic girdle: not visible; (5) Pectoral girdle: not visible; (6) Wing: thickening mild; most noticeably nearest midline; (7) Head: normal (no concavity noted in skin near eyes or mouth).



d. **Body Condition Score 4:** Dorsal coelomic surface: pectoral musculature shows moderate convexity nearest the midline; (2) Ventral coelomic surface: moderate convexity; (3) Gill arches: not visible; (4) Pelvic girdle: not visible; (5) Pectoral girdle: not visible; (6) Wing: thickening moderate; can be seen throughout the wing musculature; (7) Head: normal (no concavity noted in skin near eyes or mouth).



e. **Body Condition Score 5:** (1) Dorsal coelomic surface: pectoral musculature shows severe convexity nearest the midline; (2) Ventral coelomic surface: severe convexity; (3) Gill arches: not visible; (4) Pelvic girdle: not visible; (5) Pectoral girdle: not visible; (6) Wing: thickening severe; extreme cases may have wing thickening to the wingtips; (7) Head: normal (no concavity noted in skin near eyes or mouth).