

## Research Article

# Assessment of Body Condition in Asian Elephants (*Elephas maximus*)

C. Wemmer,<sup>1\*</sup> V. Krishnamurthy,<sup>2</sup> S. Shrestha,<sup>3</sup> L.-A. Hayek,<sup>4</sup> Myo Thant,<sup>5</sup> and K.A. Nanjappa<sup>6</sup>

<sup>1</sup>Conservation and Research Center, Front Royal, Virginia

<sup>2</sup>Salim Ali Centre for Ornithology and Natural History, Coimbatore, Tamilnadu, India

<sup>3</sup>Albert Einstein College of Medicine, Institute for Animal Studies, Bronx, New York

<sup>4</sup>National Museum of Natural History, Smithsonian Institution, Washington, DC

<sup>5</sup>Myanmar Timber Enterprise, Ministry of Forestry, Mandalay, Myanmar

<sup>6</sup>Karnataka Forest Department, Mysore, India

A method of assessing body condition of Asian elephants (*Elephas maximus*) is presented. The method uses visual assessment to assign numerical scores to six different regions of the body, which are totaled to give a numerical index ranging from 0–11. The relationship between the index and morphometric variables is compared for a sample of 119 juvenile and young adult elephants from southern India, Nepal, and Myanmar. Mean ages of males and females were similar. Mean index of body condition (with standard error [SE]) was  $7.3 \pm 0.2$  points. No significant correlation was found between index of body condition and age over both sexes ( $r = 0.01$ ,  $n = 50$ ). Results were equivalent when sexes were treated separately (females:  $r = 0.03$ ,  $n = 24$ ; males:  $r = 0.01$ ,  $n = 26$ ). Sexes did not differ in height of the shoulder or body condition in our sample, but there was significant sexual dimorphism in breadth of the zygomatic arch and three measures of subcutaneous fat: girth of neck, thickness of cervical fold, and thickness of anal flap. These three measures were also significantly correlated with each other. Our assessment method should prove a practical tool for ecologic studies, but the relationship of the index to

V. Krishnamurthy is deceased.

Grant sponsor: Program in Science and Technology Cooperation of the United States Agency for International Development; Grant number: DHR-5600-G-00-0062-00.

\*Correspondence to: C. Wemmer, 6125 Tom's Trail, Magalia, CA 95954.

E-mail: chindwin@sbcglobal.net

Received 6 January 2006; Accepted 13 February 2006

DOI 10.1002/zoo.20099

Published online 27 April 2006 in Wiley InterScience (www.interscience.wiley.com).

percentage of body fat should be determined using heavy water dilution methodology. *Zoo Biol* 25:187–200, 2006. © 2006 Wiley-Liss, Inc.

**Keywords:** fat; morphology; morphometrics; sexual dimorphism

## INTRODUCTION

Asian elephants live in seasonal environments, and almost all populations move between wet and dry season ranges that differ in availability of food, water and nutritional quality [Desai, 1991; Sukumar, 1992]. An increasing number of populations survive in lands degraded and fragmented by human activity, where conflict with agriculture is inevitable [Santiapillai and Jackson, 1990]. Because physical condition of an elephant is responsive to nutrition and conditions of habitat, assessment of body condition should prove as useful for ecologic studies as it has in other species of wildlife [Riney, 1982]. It also has special application for husbandry of domestic elephants, particularly in Asia, where as many as 15,000 elephants are maintained for domestic use [Sukumar, 1992].

Few attempts have been made to measure quantitatively the body condition of Asian elephants. No indices of body condition were used by veterinary surgeons working in elephant camps in southern Asia during the late 19th and early 20th centuries [Krishnamurthy and Wemmer, 1995b]. Evans [1910] remarked that emaciation may be so slight that the “natural depressions and projections of the surface are accentuated, or so pronounced that the beast becomes a skeleton.” The book by Evans [1910] shows a well-rounded and smoothly contoured animal as an illustration of the “ideal specimen of a timber-working elephant.” Eltringham [1982] noted that debility and pinguidity are easily detected in African elephants, but that the intermediate stages of greatest interest are most easily gauged by “general body configuration.” He also notes that depressions and boniness of appearance increase with age. Albl [1971] examined carcasses of 240 African elephants in Zambia in an effort to detect simple, condition-dependent, physical changes that could be used as criteria to classify physical condition. He noted that the best external features indicating poor condition are a pronounced lumbar depression and a prominent lateral wing on the ilium of the pelvic girdle [Albl, 1971].

We developed an index of body condition for Asian elephants that relies on visual assessment of mass (muscle and fat) associated with skeletal structures, such as the head, shoulder, rib cage, and pelvic girdle. This study describes the method and compares it with other indirect measures of body fat to examine the relationship between body conditions and other morphometric variables. We examined sexual differences in body condition because energetic costs are likely to differ between males and females in polygynous and sexually dimorphic species, such as the Asian elephant [Eisenberg, 1981, Clutton-Brock et al., 1982]. Because plane of nutrition differently affects animals of differing age we also examined age-related differences in body condition using height of shoulder as an indicator of age as done in other species of ungulates [Caughley, 1970, 1971; Brooks, 1978].

## MATERIALS AND METHODS

### Subjects and Study Area

We examined degree of fatness in various parts of the body of domestic elephants during visits to elephant Forest Department camps in Tamil Nadu and Karnataka states, India (Mudumalai, Indiragandhi, and Rajivgandhi national parks), Nepal (Chitwan, Bardia, and Kosi Thappu national parks), and Myanmar (Sagaing Division). Data were collected during both the cool and hot dry seasons, between December and late April, when conditions of forage were poor. The management systems in these regions have been described elsewhere to various degrees [Krishnamurthy and Wemmer, 1995a; Shrestha et al., 1998; Aung and Nyunt, 2002; Kharel, 2002]. The elephants at all sites receive daily food supplements such as whole rice and boiled grains. South Indian and Myanmar elephants are fettered and allowed to graze in the forest at night, whereas Nepalese elephants are staked at night and given cut fodder (grass and browse). There were only a limited number of elephants of known age in the camps of the Forest Departments of Tamil Nadu and Karnataka. However, we were able to measure and compare individuals differing in estimated or known age, body size, and body condition [Wemmer and Krishnamurthy, 1992]. In our sample of 119 elephants, 61 (51%) were females and 58 (49%) were males. Fifty elephants were of known age; ( $n = 50$ , mean =  $17.5 \pm 1.8$  years, range = 4–46 years). No significant sexual difference in mean age was found in this sample (females:  $n = 24$ , mean =  $17 \pm 2.6$  years, range = 4–46 years; males:  $n = 26$ , mean =  $17.9 \pm 2.6$  years, range = 4–46 years). Because the *F*-test on mean ages of sexes and the test for homogeneity of variance yielded non-significant differences, the data were pooled when appropriate. Standard error of the mean (SEM) is used throughout this study.

### Index of Body Condition

Determination of the range of body condition was aided by black-and-white and color photographs of over 200 individuals accumulated in the 1980s. After range of condition was examined and noted for each of several regions of the body, a preliminary index of body condition was drafted, using morphologic features of the head, body, and tail. Our criteria were tested on domestic elephants in 1990 by six researchers with the Elephant Ecology Project of the Bombay Natural History Society in Mudumalai National Park, and we then revised them to improve the accuracy of the described physical criteria (Table 1).

The finalized methods, which were based on the most easily observable measures involving mutually exclusive and exhaustive criteria, can be used under a variety of lighting conditions, but bright overhead sunlight facilitates accurate evaluation. Observers can quickly assess domestic elephants by viewing various regions of the body from different angles and should ask the handler (mahout) to make the animal move and shift its weight, because postural adjustments often help the observer decide which criterion best describes the condition. Assessing wild elephants requires more time because the observer must wait for the animal to move and show its configuration from different perspectives. Reclining elephants can not be assessed easily because of unusual postural adjustments and positioning of the viscera.

**TABLE 1. Criteria and point scores used to assess body condition in Asian elephants**

Body region/score	Criteria
<b>A. Head: temporal depression (view from several angles)</b>	
2 points	Full and convex in outline when viewed from behind (at the level of the neck or shoulder); frontal ridge vaguely outlined at best.
1 point	Slightly to moderately concave; frontal ridge defined.
0 points	deeply concave; frontal ridge forms a crater-like rim around the temporal depression.
<b>B. Scapula (shoulder blade) (view from side)</b>	
2 points	Spinous process of the shoulder blade not visible, or slightly visible when the foreleg is in certain positions.
1 point	Spinous process visible as a vertical ridge with a concavity between the ridge and the and the posterior edge of the scapula.
0 points	Spinous process pronounced and bladelikey with the acromial process pronounced as a knot.
<b>C. Thoracic region (view from side)</b>	
2 points	Ribs not visible, barrel smooth.
1 point	Some ribs visible, but the extent and demarkation not pronounced.
0 points	Many ribs strongly demarcated (even behind the scapula) with pronounced intercostal depressions.
<b>D. Flank area (immediately in front of pelvic girdle) (view from side and behind)</b>	
1 point	No depression visible; flank bulges outwards in front of the pelvis.
0 points	Depression visible as a sunken area immediately in front of pelvis.
<b>E. Lumbar vertebrae (behind ribs and in front of pelvis) (view from behind, an elevated vantage point may be necessary)</b>	
2 points	Not visible, lower back smooth and rounded.
1 point	Visible as a ridge; skin slopes away from the top of the ridge; height of the vertebrae does not exceed width.
0 points	Visible as a knife-like blade; sides of spinal ridge almost parallel, and the height equal to or exceeds the width.
<b>F. Pelvic bone (external angle of the ilium) (view from several angles)</b>	
2 points	Not visible (or slightly visible); rump region between the ilium and caudal vertebrae filled with tissue (and not forming a depressed zone).
1 point	Visible but not pronounced; the rump is a slightly depressed zone between the ilium and the caudal vertebrae.
0 points	Visible as a jutting bone; rump is a pronounced sunken zone between ilium and the caudal vertebrae.

When a particular body region is intermediate between two criteria, an intermediate point score (i.e. 0.5, 1.5 points) should be assigned.

To use the index and reduce subjectivity and inaccuracy, evaluators must become familiar with the range of conditions possible in domestic elephants (Figs. 1,2,3,4). The evaluator scores the elephant on the basis of six regions of the body using two or three criteria for each body region (Table 1). The six scores are then totaled to obtain the index.




Fig. 1. Head configuration of cow elephants showing temporal depression from a frontal (A) and lateral (B,C) perspective. A,B: Receives a score of 1 point. C: Receives no points. See Table 1 for description of criteria.



Fig. 2. Body configuration of (A) young adult bull in good body condition (ca. 8 points); notice the smooth shoulder and rib cage, absence of flank depression (pelvic bone not clearly discernible); (B) a thin male in late middle age in poor body condition (2–3 points); (C) a thin-bodied old cow (notice that the ribs are not visible) (2 points); (D) an emaciated old cow with strongly demarcated scapula, ribs, and pelvic girdle (0 points). See Table 1 for description of criteria.

### Comparative Measures of Subcutaneous Fat

To examine age-related variation in topography of the head and deposition of fat we used a Haglof aluminum forestry caliper (Haglof, Inc., Madison, MS) for the following measurements. The maximum breadth of the head at zygomatic arches (ZB) as a dimension of reference, and the breadth of the head at the temporal fossa (intertemporal breadth or ITB) midway between the posterior corner of the eye and dorsal attachment of the ear served as the comparative measurements [Wemmer and Krishnamurthy, 1992]. Similarly, we measured the straight distance between the posterior corner of the eye and the upper origin of the ear (EELs), and compared this dimension of reference with the curved distance (EELc) obtained when a cloth tape was pressed against the skin of the temporal depression [Wemmer and Krishnamurthy, 1992]. The difference between the dimensions of reference and comparative measures is presumed to reflect differences in the amount of fat in the underlying tissue. Ratios between these measures (EELs with EELc and ZB with ITB) and their log differences were correlated with various other measures including age and size of body (height of shoulder). Because we employed the descriptive statistics of correlation, rather than the predictive capabilities, no assumptions of normality (and transformations) were necessary [Hays, 1974; Hayek and Buzas, 1997]. Because both parametric and nonparametric correlation analyses yield the

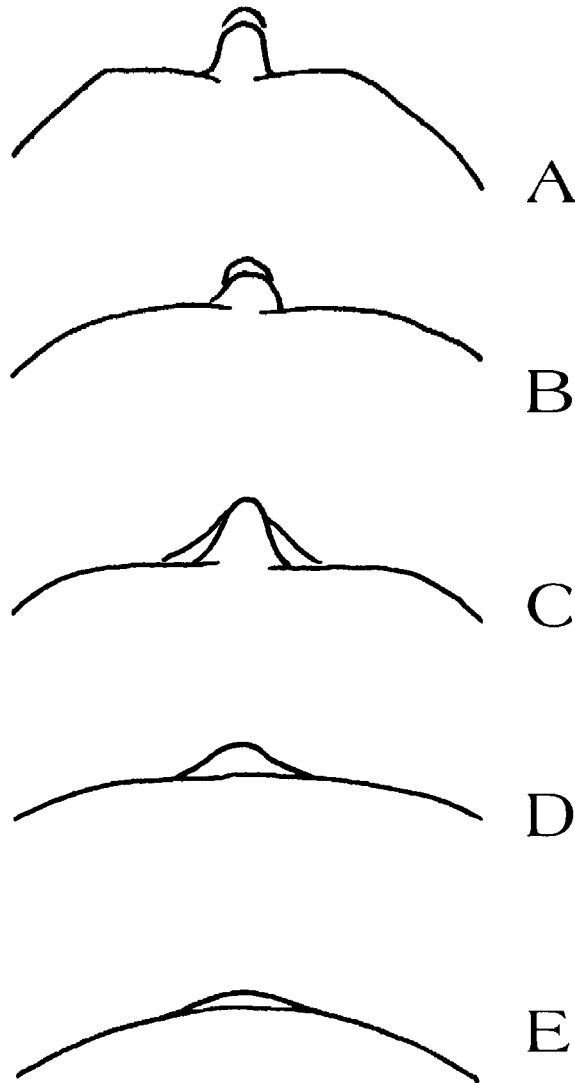


Fig. 3. The degrees of visibility of the lumbar vertebrae of Asian elephants of differing body condition (as seen from behind; sketches from photographs). In the top two profiles (**A**,**B**) the lumbar vertebrae and the thoracic vertebrae beyond them are clearly visible and blade-like (0 points); the middle example (**C**) shows the vertebral ridge with sloping tissue on the sides (1 point); the fourth example (**D**) is less pronounced and would receive 1.5 points. In the bottom example (**E**), as is seen in the rare fat elephant, underlying tissue obscures the lumbar vertebrae (2 points). See Table 1 for description of criteria.

same decisions when used with continuous data, we chose only to quote the parametric version at the  $\alpha = 0.05$  level.

Four additional variables were measured to examine individual variation in indicators of subcutaneous fat. The circumference of the neck and chest were measured with a tape measure, and the diameter of folds of skin on the anal flap and side of the neck (cervical fold) were measured with the use of a Lange Skinfold




Fig. 4. Views of the pelvic girdle and associated tissue. **A:** The external angle of the ilium is visible in the middle of the photo (*left arrow*), and the caudal vertebrae appear as a distinct ridge (*right arrow*). The tissue of the rump is depressed between these two features. The degree of depression of the hip tissue is more visible when viewed from anterior position (**B**) and a tangential posterior angle (**C**) (notice mass of tissue at base of tail—the anal flap). See Table 1 for description of criteria.



Caliper (Pro-Med Products Inc., Atlanta, GA). No significant differences were found in measures of fat on the right and left side of the neck and the anal flap (Fig. 4C); so a mean of the two measures was used as a measure of body size. Height of the shoulder, determined with a caliper, was used as a surrogate measure for body size.

## RESULTS

Our observations indicate that Asian elephants differ in the extent to which different regions of the body store fat. The head, shoulder and pelvic girdle show a range of condition from full and convex to highly angular and contoured (Figs. 1,2). The temporal fossa, zygomatic arches, supraorbital bars, and the angle of the mouth are not pronounced in fat animals, but become sharply outlined in thin animals. The scapulae, ribs, and vertebral column are smooth and rounded in fat animals, but acquire increasing skeletal definition with loss of fat. In the rare fat animal, the pelvic girdle and lumbar region are rounded and full (Figs. 2,3). Most elephants have a distinctive caudal ridge anterior to the tail, and the musculature of the hips forms a depressed zone between the caudal ridge and the ilium of the pelvic girdle (Fig. 4). In very thin animals the transverse processes of the tail and the caudal ridge are clearly visible. The anal flap often retains its fleshy character in otherwise bony elephants (Fig. 4C).

Using the entire sample of both known and estimated age elephants, the mean index of body condition was  $7.3 \pm 0.02$  points ( $n = 119$ ). No significant correlation was found between scores of body condition and age ( $r = 0.011$ ). Likewise, there was no correlation when sex data were treated separately (females:  $r = 0.03$ ,  $n = 24$ ; males:  $r = 0.01$ ,  $n = 26$ ). The condition of males and females as determined by a Student's *t*-test was not significantly different at the 0.05 level.

Shoulder height and neck and chest girth had similar profiles of relationships. Shoulder height was more highly correlated with chest girth than with neck girth ( $r = 0.95$  vs.  $0.86$ ,  $n = 119$ ), but all three variables were significantly correlated at the 0.05 level with age as represented by height of shoulder ( $r = 0.86$ ); chest girth ( $r = 0.88$ ), neck girth ( $r = 0.85$ ). Significant sexual dimorphism ( $P = 0.01$ ) was apparent in the girth of the neck (males: mean =  $2.01 \pm 0.05$  m; range = 1.31–2.74,  $n = 58$ ; females: mean =  $1.85 \pm 0.04$  m, range = 1.19–3.00), and breadth of the zygomatic arch (males: mean =  $61.3 \pm 1.1$  cm, range = 44.1–75,  $n = 58$ ; females: mean =  $58.2 \pm 0.8$  cm, range = 44.1–71,  $n = 61$ ;  $P = 0.03$ ).

## Comparative Measures of Deposition of Fat

In the male and female elephants, age was significantly correlated with both ITB and ZB, but not correlated with the ratio ITB:ZB (Table 2), nor with a logarithmic transformation of the ratio. Age (and its proxy of shoulder height) was also highly correlated with EELs and EELc, as well as the ratio EELs:EELc (Table 3). The ratio EELs:EELc was significantly correlated with the height of shoulder, girth of chest, girth of neck, ITB, and ZB (Table 3). The ratio ITB:ZB, on the other hand, was not correlated with any other variable for either sex (Table 3). However, the ratio ITB:ZB was significantly correlated with EELs:EELc in males ( $r = 0.39$ ,  $n = 58$ ,  $P = 0.003$ ).

Thickness of the cervical fold was significantly correlated with height of shoulder and girth of neck (both variables,  $r = 0.24$ ,  $P = 0.04$ ,  $n = 75$ ), and thickness

**TABLE 2. Correlation of sex with two sets of head measurements and their ratios in a sample of 24 female and 26 male Asian elephants<sup>a</sup>**

Sex	ITB	ZB	ITB:ZB	EELs	EELc	EELs:EELc
Female	0.85**	0.85**	0.14 <sup>ns</sup>	0.89**	0.90**	-0.25*
Male	0.79**	0.87**	-0.29 <sup>ns</sup>	0.86**	0.88**	-0.66*

<sup>a</sup>ITB, inter-temporal breadth; ZB, zygomatic breadth; EELc, straight ear-eye length; EELs, curved ear-eye length.

\*Significant at 0.00 level.

\*\*Significant at 0.000 level.

<sup>ns</sup>Not Significant.

of the anal flap was significantly correlated with height of shoulder, as well as girth of chest and neck ( $r = 0.54$ ,  $P = 0.001$ ;  $r = 0.55$ ,  $P = 0.001$ ;  $r = 0.51$ ,  $P = 0.001$ ;  $n = 119$ , respectively). Neither variable of skin thickness was significantly correlated with the index of body condition. Males had significantly greater mean thickness values of both the cervical fold and anal flap than females (neck: female: mean =  $20.5 \pm 0.6$ , range = 10–35,  $n = 43$ ; male: mean =  $24.7 \pm 1.1$ , range = 15–35.5,  $n = 32$ ;  $P = 0.001$ ; anal flap: female: mean =  $19.29 \pm 0.6$ , range = 11–27.5,  $n = 43$ ; male: mean =  $23.72 \pm 1.01$ , range = 14–38.5,  $n = 32$ ;  $P = 0.0001$ ). Sex differences were also found in girth of neck (male: mean =  $2.01 \pm 0.05$  m, range = 1.31–2.74; female: mean =  $1.85 \pm 0.04$  m, range = 1.42–3.00;  $P = 0.01$ ), and ZB (male: mean =  $61.3 \pm 1.12$  cm, range = 44.1–75.0; female: mean =  $58.15 \pm 0.84$  cm, range = 44.1–71.0;  $P = 0.03$ ).

## DISCUSSION

The level of reserves of fat is a useful indicator of a population's general well-being, but obtaining field measures of body fat is a challenge. The relationship of most indices methods to actual composition of the body has not been determined [Robbins, 1983]. Robbins [1983] states that minimal variation and a linear or curvilinear relationship are two factors that enhance the value of indices as indicators of body composition. Indices that measure "an off-off process, such as a body fat reserve that is the last to be mobilized and first to be replenished and maintains a constant value over a wide range of conditions, will be far less useful than one that provides a continuous, accurate and easily determined indication of body composition." We found no single variable of subcutaneous fat (e.g., cervical fold, anal flap, girth of chest and neck, and the ratios EELs:EELc and ITB:ZB) that closely parallels the index of body condition. The index gauges subcutaneous fat and intermuscular fat in several parts of the body. In a study of caribou, Adamczewski et al. [1987] noted that starving deer utilized subcutaneous fat and fat of the rump before fat of the viscera and marrow. We infer from the differing appearance of animals seen in Figures 1,2,3,4 that elephants follow the general pattern observed in ungulates. Subcutaneous changes in mass of tissue may be sensitive indicators of composition of the body, but additional studies must be undertaken to test this hypothesis. Methodology that measures the dilution of heavy water in the body is one possible means of doing this [Hildebrand et al., 1998].

There was no correlation between the index of body condition and age in the Myanmar population. With a mean age of  $17.5 \pm 12.7$  years, this was a young

**TABLE 3. The correlation of the two head measurement ratios, EELS:EELc and ITB:ZB, with eight variables in male and female Asian elephants<sup>a</sup>**

Variable	EELS:EELc						ITB:ZB					
	Females			Males			Females			Males		
	<i>r</i>	<i>n</i>	<i>P</i>	<i>r</i>	<i>n</i>	<i>P</i>	<i>r</i>	<i>n</i>	<i>P</i>	<i>r</i>	<i>n</i>	<i>P</i>
Shoulder height	-0.36	61	.004	-0.49	58	.000	-0.06	61	NS	-0.17	58	NS
Chest girth	-0.31	61	.015	-0.48	58	.000	-0.08	61	NS	-0.15	58	NS
Neck girth	-0.30	61	.016	-0.50	58	.000	0.02	61	NS	-0.18	58	NS
ITB	-0.39	61	.002	-0.34	58	.009	0.24	61	NS	0.08	58	NS
ZB	-0.44	61	.000	-0.47	58	.000	-0.10	61	NS	-0.26	58	NS
Tail flap	-.003	43	NS	-0.25	32	NS	0.12	43	NS	0.06	32	NS
Neck fold	0.31	43	.04	-0.33	32	NS	-0.03	43	NS	-0.01	32	NS
Body condition index	-0.15	61	NS	0.06	58	NS	0.05	61	NS	0.10	58	NS

<sup>a</sup>ITB, inter-temporal breadth; ZB, zygomatic breadth; EELS, straight ear-eye length; EELc, curved ear-eye length; NS, not significant.

population in which most animals had not achieved adult body size; greater variation in condition of the body would be expected in a population of middle-aged and reproducing elephants. The predominance of young adults in the sample is also the most likely explanation of why no significant sex difference was evident in height of shoulder.

Attempts to find a single morphometric measure concordant with the index of body condition were not successful. Nearly all morphometric variables were correlated with age and height of shoulder. In females, however, neither ratio of the temporal fossa (EELs:EELc and ITB:ZB) was correlated with age. The negative value of the correlation coefficient of these ratios indicates that as males grow older, the disparity between the straight and curved measurement of the EEL increases. The similarity in direction and magnitude of the same relationship in females suggests, with an increase in sample size, the ratio may prove to be useful discriminate of age for females as well. Although we considered these ratios to be prospective indicators of condition, they did not correlate with the index of body condition. The temporal fossa of males shows increasing concavity with age, but like other individual measures, it did not reflect overall body condition. In neither sex did the ITB:ZB ratio correlate with age or index of body condition.

Girth of chest and neck were more strongly correlated with age than with the index of body condition. Why do indirect measures of fat from various regions of the body correlate so poorly with the index of body condition? Statistically the index of body condition is a conglomeration of variables that behaves like an average. Individual differences in the location of storage of fat between animals are de-emphasized by reliance on a composite value, based upon several measures.

Sexual differences were evident in the ratios computed for the temporal fossa, anal flap, and cervical fold. We infer from these differences that the anal flap of males is a depot of fat of higher physiologic priority than that of females. The greater girth of the neck and size of the cervical fold, however, may reflect thicker skin associated with a dermal shield because fighting in male Asian elephants involves frontal engagement of the trunks and tusks. Greater girth of neck also contributes to the characteristic male conformation we have observed in tuskless males, and possibly to sexual recognition. The head seems to be a low priority storage area of fat, whereas the body and pelvic girdle are storage sites of medium priority.

While developing the index of body condition, we instructed a number of Asian veterinarians and wildlife biologists in its use. The method is easily learned, especially when photographs and sketches are used to clarify the criteria. This method allows quick assessment of body condition of captive elephants where the observer can easily view the animals from different angles. When assessing the condition of wild Asian elephants, binoculars are usually required and greater time is necessary than when viewing captive animals at close range. The application of the method will allow wildlife biologists to examine body condition of Asian elephants under differing environmental and demographic conditions. The habitats of wild elephants differ from dry scrub jungle to moist evergreen forest, and from large protected areas to small fragments of habitat where disturbance is chronic. The conservation of these populations will benefit from study and the application of additional methods. The index reported here can be used to assess relative differences between individuals and populations by testing the mean scores for two or more groups of adequate size using a *Z*-test.

## CONCLUSIONS

We examined morphometric variation in specific body parts of domestic Asian elephants to determine their usefulness as indicators of subcutaneous and intermuscular fat, and we then designed an index of body condition based on visual criteria for six parts of the body. We found no single variable of subcutaneous fat (e.g., cervical fold, anal flap, girth of chest and neck, and the ratios EELs:EELc and ITB:ZB) that closely parallels the index of body condition. Statistically the index of body condition is a conglomeration of variables that behaves like an average. Individual differences in the location of storage of fat between animals are de-emphasized by reliance on a composite value, based upon several measures. The index should prove useful to zoo and wildlife biologists who wish to assess body condition of captive and wild elephants, but studies of the body composition of elephants should be undertaken to validate the relationship of the body condition index to physiologic measures of body fat.

## ACKNOWLEDGMENTS

We thank the Forest Departments of Karnataka and Tamil Nadu for access to timber elephant camps. The Department of National Parks and Wildlife Conservation, Nepal, kindly allowed access and assistance to S. Shrestha for investigations there. In Myanmar, the Ministry of Forestry and Department of Planning and Statistics kindly made elephant camps available to us in 1995. We also thank Daw Khyne U Mar for helping make local arrangements in Myanmar. The manuscript benefitted from reviews by M. Allen, S. Monfort, W. McShea, and R. Sukumar. B. Senior helped with the final preparations of the manuscript.

## REFERENCES

- Adamczewski JZ, Gates CC, Hudson RJ. 1987. Fat distribution and indices of carcass composition in Coats Island caribou (*Rangifer tarandus groenlandicus*). *Can J Zool* 65:368–74.
- Albl P. 1971. Studies on assessment of physical condition in African elephants. *Biol Conserv* 3: 134–40.
- Aung T, Nyunt T. 2002. The care and management of the domesticated Asian elephant in Myanmar. In: Baker I, Kashio M, editors. *Giants on our hands*. Bangkok, Thailand: FAO Regional Office for Asia and the Pacific. p 89–102.
- Brooks PM. 1978. Relationship between body condition and age, growth, reproduction and social status in impala, and its application to management. *S Afr J Wildl Res* 8:151–157.
- Caughley G. 1970. Fat reserves of Himalayan thar in New Zealand by season, sex, area and age. *N Z J Sci* 13:209–19.
- Caughley G. 1971. Demography, fat reserves and body size of a population of red deer *Cervus elaphus* in New Zealand. *Mammalia* 35: 369–83.
- Clutton-Brock TH, Guinness FE, Albon SD. 1982. Red deer, behavior and ecology of two sexes. Chicago, IL: University of Chicago Press. 1655p.
- Desai AA. 1991. The home range of elephants and its implications for management of the Mudumalai Wildlife Sanctuary, Tamil Nadu. *J Bombay Nat Hist Soc* 88:145–56.
- Eisenberg JF. 1981. *The mammalian radiations*. Chicago, IL: University of Chicago Press. 610p.
- Eltringham SK. 1982. *Elephants*. Poole, UK: Blandford Press. 262p.
- Evans GH. 1910. *Elephants and their diseases, a treatise on elephants*. Rangoon, Burma: Government Printing Office. 323p.
- Hayek L- A, Buzas MA. 1997. *Surveying natural populations*. New York, NY: Columbia University Press. 561p.
- Hays WL. 1974. *Statistics for the social sciences*, 2nd ed. London, UK: Holt, Rinehart, and Winston. 954p.
- Hildebrand GV, Farley SD, Robbins CT. 1998. Predicting body condition of bears via two field methods. *J Wildl Manage* 62:406–9.
- Kharel FR. 2002. The challenge of managing domesticated Asian elephants in Nepal. In: Baker I, Kashio M, eds. *Giants on our hands*.

- Bangkok, Thailand: FAO Regional Office for Asia and the Pacific. p 103–10.
- Krishnamurthy V, Wemmer C. 1995a. Veterinary care of Asian timber elephants in India: historical accounts and current observations. *Zoo Biol* 14: 123–33.
- Krishnamurthy V, Wemmer C. 1995b. Timber elephant management in the Madras Presidency of India (1844-1947). In: Daniel JC, Datye H, editors. *A week with elephants*. Bombay, India: Oxford University Press and Bombay Natural History Society. p 456–72.
- Riney T. 1982. *Study and management of large mammals*. Chichester, NY: John Wiley and Sons. 552p.
- Robbins, CT. 1983. *Wildlife feeding and nutrition*. New York, NY: Academic Press. 343p.
- Santiapillai C, Jackson P. 1990. *The Asian elephant, an action plan for its conservation*. Gland, Switzerland: IUCN. 79p.
- Shrestha SP, Ullrey DE, Bernard JB, Wemmer C, Kramer DC. 1998. Plasma vitamin E and other analyte levels in Nepalese camp elephants (*Elephas maximus*). *J Zoo Wildl Med* 29: 269–78.
- Sukumar R. 1992. *The Asian elephant, ecology and management*. Cambridge, UK: Cambridge University Press. 272p.
- Wemmer C, Krishnamurthy V. 1992. Methods of taking standard measurements in live domestic elephants. In: Silas EG, Nair MK, Nirmalan G, editors. *The Asian elephant: ecology, biology, diseases, conservation and management*. Trichur, India: Kerala Agricultural University. p 34–7.